


Histomorphological and histochemical Study of the jejunum in moorhen (*Gallinula chloropus*) in Iraq

¹Rafal Yousuf , ²Azhar saleem Khalaf

^{1,2}Department of Anatomy, Embryology and Histology, Collage of Veterinary Medicine, University of Baghdad, Iraq.

²E-mail: Azhar.s@covm.uobaghdad.edu.iq

jejunum, ileum

Abstract

The goal of the current investigation was to gather information on the histology and histochemical composition of the jejunum in moorhens (*Gallinula chloropus*). In order to conduct the current investigation, six moorhens were gathered. They were purchased from regional vendors in particular markets in Baghdad, Iraq. To collect the intestine, birds were put down after being dissected, and the specimens were then fixed in 10% neutral buffered formalin. The blocks were sectioned at 6 m thickness and stained with Mayer's hematoxylin and eosin, Masson trichrome stain, periodic acid Schiff reagent (PAS), and Alcian blue stain (AB)PH-2.5 ,after being thoroughly fixed. The specimens were then cleared in xylene and embedded in paraffin wax. According to the Gross findings, the small intestine is made up of the duodenum, the jejunum, and the ileum. Histologically, the mucous membrane was thrown into large numerous villi in the jejunum, showing blunt apical part and wide basal part with thin layer of muscularis mucosa. The submucosa was thin layer of connective tissue. Below the submucosa was thick layer arranged in a thick circular and thin longitudinal. According to histochemical results, the PAS stain had a negative reaction on columnar cells while having a positive reaction on goblet cells. When the AB (pH 2.5) was applied, the wall displayed epithelial cells that stained negatively while the goblet cells responded favorably to their acidic mucopolysaccharides.

Key words: Histomorphology, Histochemical, moorhen, duodenum

I. INTRODUCTION

The avian class has the second-highest number of species among vertebrates. There are about 8,600 different kinds of birds in the globe, and they have all evolved to suit their various surroundings, food supplies, and lifestyles. Birds have various feeding behaviors, and these behaviors are reflected in the variations in the anatomy of their digestive systems (1). Carnivorous birds have fully developed small intestines, but the cecum does not grow as well as the small



intestine of herbivores (2). The small intestine of birds performs similar tasks to those of mammals, including nutrient absorption, food processing employing enzymes, and bile excretion from the pancreas and liver (3). 2014 (4) Dhyaa, Ab. Abood; et al .

The birds differ in strain, order, and diet, with the order Passeriformes being the largest and the order Struthioniformes being the smallest (AL-Taai & Nsiaf 2020)(5). Various types of birds were studied by several investigators over the previous century(6-7 -8) - Mohammed HH, Abood DA, and Ezaldeen L. (2018) (9).

The birds differ in strain, order, and nature of diet, with the order Passeriformes being the largest and the order Struthioniformes being the smallest(10) Al-Saffar F.J. and Al-Samawy, (2015) and in birds (11) Khaleal.m and Raghad J.(2016) (12) .

studies were done to investigate how dietary habits have shaped the morphological features and consequently affected physiological activities on the digestive organs. The moorhens are little water birds with a red or white forehead pattern that inhabit riverbanks, water shelves, and areas with reeds and other aquatic vegetation (Steven, 2010) (13). The moorhens may be found in the Arab homeland, where they can be found in Morocco, Egypt, and Sham in addition to extending eastward to Iraq and the Arab gulf as far as Iran's borders, middle Asia, and the majority of European nations (Jassem et al., 2016)(14).

According to Famous et al. (2019), moorhen are omnivores and consume vegetables, leaves, seeds, mollusks, amphibians, and arthropods. 15. Birds must consume a lot of food because their incredibly high metabolism cannot keep up with their needs. Accordingly, Abood, D.A. Hussain ZM (2017) and Iman M. Khaleel et al.

(2017) found that birds had higher metabolic rates than other animal species, which caused them to consume more food in proportion to their size. From the distal end of the duodenal loop to the ileum, the jejunum, the second segment of the small intestine, was present (18).Al-Samawy (2016) and Al-Saffar F.J. According to our knowledge, there have been very few local studies undertaken to investigate the histomorphological and histochemical aspects of the jejunum of the moorhen (*Gallinula chloropus*). This study was conducted to wrap up the earlier studies that dealt with the digestive tract in birds.

II. MATERIALS AND METHODS

The current study involved the collection of six moorhens (*Gallinula chloropus*). They were purchased from local suppliers in Baghdad markets. Prior to dissection, birds were euthanized with an intravenous dose of sodium pentobarbitone (80 mg/ kg), then fixed on a dissecting board. To see the coelomic viscera, an incision was created in the midline of the abdominal wall. To remove blood or other adherent debris, the jejunum was rinsed with regular saline solution. The contents of the jejunum were extracted with mild pressure and then rinsed with normal saline. Abdul Razzaq Baker and Iman Mousa Khaleel (2018) 20,



The tissues were preserved in 10% neutral buffered formalin for the histopathological investigation. After well fixation, the specimens were dehydrated by passing them through a series of ascending ethanol for 2 h (70, 80, 90, and 100%) and then cleared in xylene for 1 h before being embedded in paraffin wax and sectioned at 6 m thickness and stained with one of the following stains: Mayer's hematoxylin and eosin routine stain for identifying general features, masson trichrome stain for staining collagenous and smooth muscle fibres. Merhish.M and Khalaf.AS (2010) 21.The fixed specimens were sectioned at 6 m and stained with one of the stains listed below to conduct the histochemical investigation. The PAS alone was used for the illustration of the goblet cells and the basement membranes of the epithelial lining the jejunum, and Alcian blue (AB) (pH 2.5) was used for the determination of the acidic mucin, which was then examined and photographed by microscope, using a digital camera.

III. RESULTS AND DISCUSSION

The moorhen's jejunum was crudely organised in the form of spiral coils. This organ resembled that of other avian species such as domestic fowl²² and African pied crow (*Corvus albus*)²³. It occupied the majority of the coelomic cavity, a characteristic shared by all avian species ^{24 -25}.(Fig.1-2) Histologically, the jejunum mucous membrane was divided into multiple big villi with a blunt apical part and a broad basal section. The epithelial lining was represented by a single layer of tall columnar cells in both villi and crypts, which was consistent with what Zaher et al. (26) observed in the common quail (*Coturnix coturnix*). Lubricant crypts were short and simple tubular channels that opened at the bases of villi and occupied the majority of the thickness of the lamina propria till the muscularis mucosa. The lamina propria is made up of loosely packed connective tissue that contains blood arteries and muscle fibres, similar to what Rodrigues et al.¹⁸ discovered in blue and yellow macaws. Muscularis mucosa (smooth muscle fibres organised lengthwise). In contrast, two layers of muscularis mucosa were found in the jejunum mucosa of an ostrich (*Struthio camelus*)²⁷. Whereas in the jejunal mucosa of the African pied crow (*Corvus albus*)²³. Tunica serosa was made up of a layer of simple squamous epithelium with a thin layer of loose connective tissue underneath (Fig. 3, 5). Histochemical investigation These staining techniques were used to determine the presence or absence of neutral and acidic mucins. Jejunum: The PAS stained negatively the simple columnar cells that lined these villi, whereas the goblet cells were highly responded with this technique (Fig. 4). The results were comparable to those recently published by Andleeb et al.²⁸, in which epithelial goblet cells were moderately stained with PAS for neutral mucopolysaccharide substances, and in AB (pH 2.5), the mucosal goblet cells were positively reacted, whereas the rest of the epithelial cells were negatively reacted (Fig. 6). This observation is consistent with that of Aitken ²⁹, who observed a moderate reactivity to Alcian blue staining throughout the chicken gut.

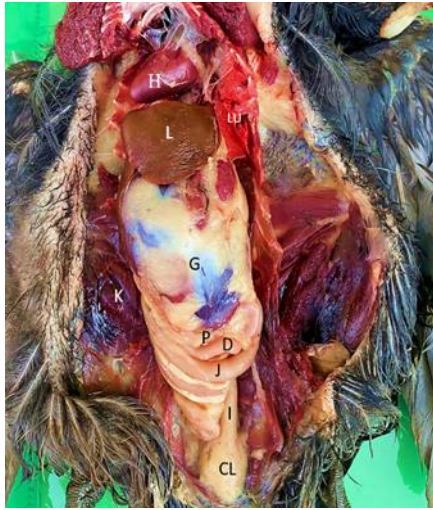


Fig. 1:Gross picture of the intestinal tract of moorhen in situ showed: duodenum (D), jejunum (J) , Ilium (I),Cloaca(CL),pancreas(P),Heart(H) ,Lung(LU),Liver(L),Gizzard(G)and kidney .

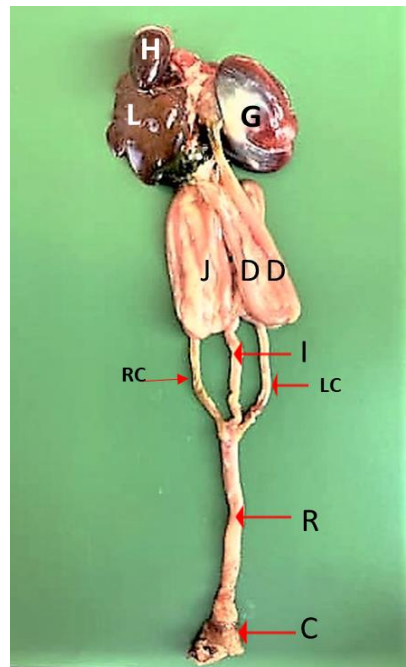
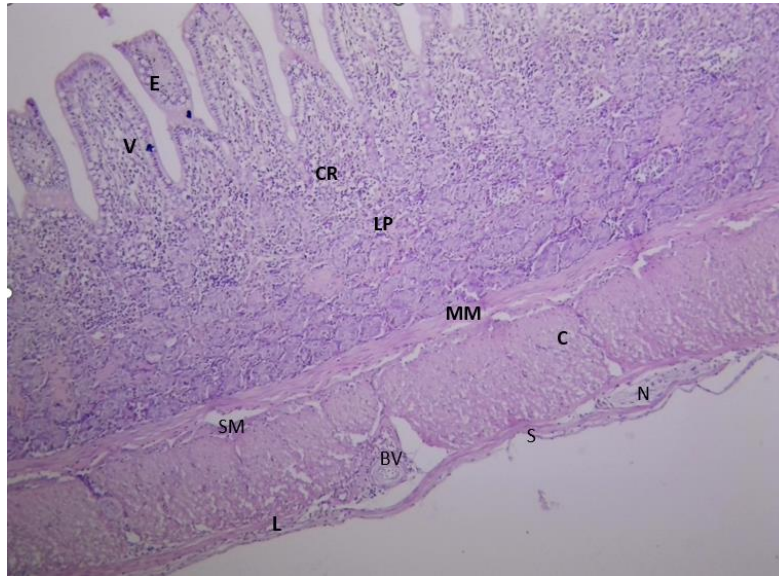


Fig 2.Gross picture of the intestinal tract of moorhen showed duodenum (D), jejunum (J) , Ilium (I) , Right cecum(RC),Left cecum(LC)Cloaca(C) ,Heart(H),Liver(L),Gizzard(G).



Histological section of the jejunum showed Villi (v), Epithelium (E) crypt off lubricant(CR),lamina propria(LP),Muscularis mucosa(MM), Tunica sub mucosa(SM),Tunica Muscularis :inner circular(C),outer longitudinal (L)smooth muscle fibers ,Blood vessels(BV) ,nerve plexus(N), T serosa (s).H and E stain.10 X.

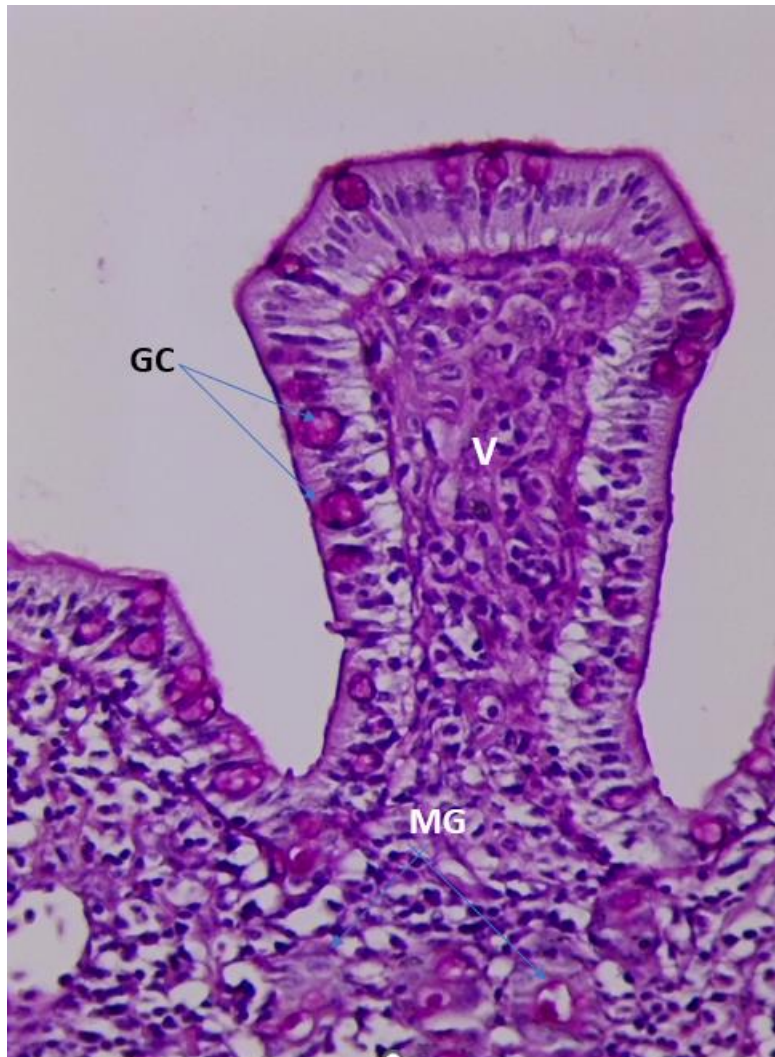


Fig. 4: Cross section of the Jejunum wall of moorhens showed : Villi (V) ,goblet cells with mucin granules (GC), crypts of lubricants (MG). PAS, X400

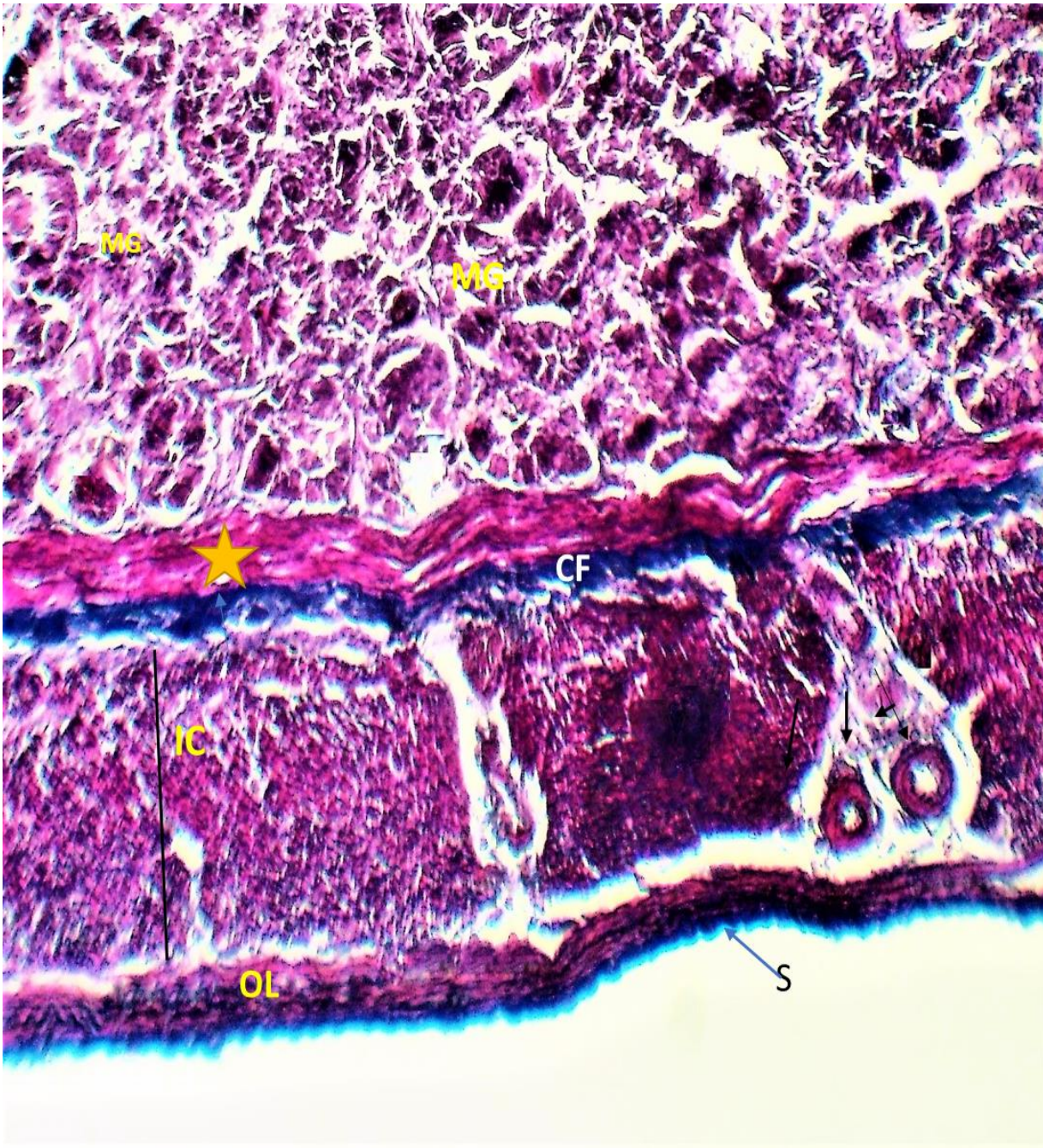

Fig. 5: Cross section of the Jejunum wall of moorhens showed: Mucosal gland(MG) Muscularis mucosa (yellow stare),Tunica muscularis (inner circular (IC),Outer longitudinal (OL), serosa(s) Blood vessels(black arrows) the connective tissue (CF), Masson's trichrome and X400

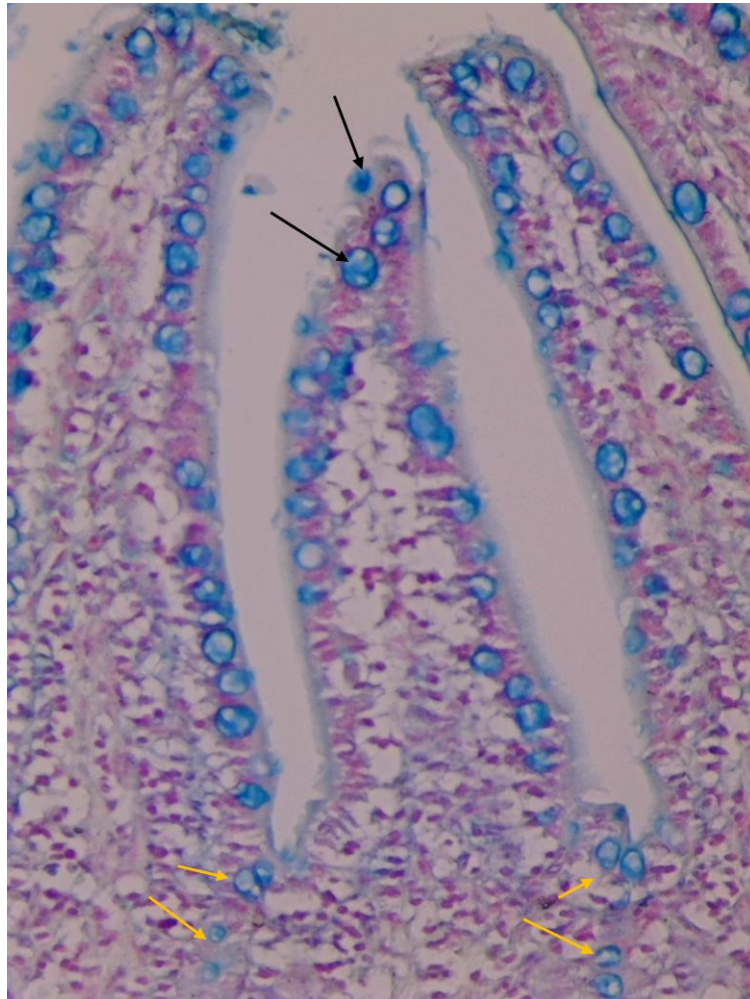


Fig. 6: Cross section of the wall of Jejunum of moorhens showed :positive reaction with Acidic mucin in villi's epithelia(Black arrows) and intestinal glands (Yellow arrows) . X400, AB (pH 2.5)

IV. CONCLUSION

Finally, the jejunum of the moorhen was covered with simple columnar cells containing goblet cells and villi. The submucosa developed from loose connective tissue. The muscularis mucosa is composed of several layers of smooth muscle fibres. Because this bird is an omnivorous species, the columnar cells of the jejunum reacted negatively to

PAS, AB (pH 2.5), whereas the goblet cells reacted positively. In reality, the latter stain is a signal for sulfated acidic mucus components, which are essential for the bird's digestion, absorption, and subsequent body growth.

V. ACKNOWLEDGEMENT

The authors strongly acknowledge the council of the Veterinary Medicine College/Baghdad University to support this research project.

VI. REFERENCES

1. Süzer B, Serbest A, Arican İ, Yonkova P, Yilmaz B. A Morphometric Study on the Skull of the Turkeys (Meleagris gallopavo). J Res Vet Med. 2018;3;37(2):36-42. DOI:10.30782/uluvfd.427228
2. Hamdi H, El-Ghareeb A, Zaher M, AbuAmod F. Anatomical, histological and histochemical adaptations of the avian alimentary canal to their food habits: II- Elanus caeruleus. IJSER. 2013;4:1355-1364.
3. Blendea, A. Cazimir, I. Cornila, N., Irimescu, I. and Damian, A. (2012). Anato-mo-histological study regarding the ovary and oviduct in different age groups in the chicken (Gallous domesticus). Veterinary Medicines J. 8: 18-27.
4. Dhyaa, Ab.Abood; Ali, F. Reshag; Azhar, S. K. and Myson, A. Ahmed (2014) : Compare anatomical and histological features of the kidney in Harrier (Circus aueroginosus), Chicken (Gallus domesticus) and Mallard duck (Anas platyrhynchos). The Iraqi Journal of Veterinary Medicine, 38(1): 107-113 AL-
5. Taai Suhaib, A.H. & Nasif, Riyadh H. 2020. Comparative histomorphological study of kidneys in pigeon (Columba livia) and starling birds (Sturnus vulgaris). Indian Journal of Forensic Medicine and Toxicology 14(4): 1707-1714:
6. King, A.S. and J. Mclelland, 1975. Outline of Avian Anatomy. 1st Edn., Bailliere, Tindall, London, pp: 33-39.
7. Allouse, B., 1961. Iraqi birds, Poultry order, Part II. Press Association, Baghdad, pp: 1-13
8. Shafeq, M., 1983. Waterfowl in Iraq and the Arab World. Dar Al-Rasheed publication, Baghdad, Iraq Pages: 242.
9. Mohammed HH, Abood DA and Ezaldeen L. (2018). Prehatching development of Gizzard in indigenous Quail(Coturixcoturnix japonica). Indian journal of Natural sciences ,9(51):15177-15183.
10. Sabat, P. and C. Veloso, 2003. Ontogenic development of intestinal disaccharidases in the precocial rodent *Octodon degus* (Octodontidae). Comp. Biochem. Physiol. Part A: Mol. Integr. Physiol., 134: 393-397. [CrossRef](#) | [Direct Link](#) |
11. Al-Saffar F.J. and Al-Samawy, E.R.M. (2015). Histomorphological and Histochemical Studies of the Stomach of the Mallard (Anas platyrhynchos). Asian J. Anim. Sci.



12. Iman m. khaleal and Raghad j. Salman(2016) :A comparative histological study of ceca and rectum in common kestrel (*Falco tinnunculus*) and white-eared bulbul (*Pycnonotus leucotis*) according to their food type. The Iraqi Journal of Veterinary Medicine, 40(2):48-56. 2016 84
13. Steven, B. (2010). The life of Britain's second commonest water bird.http: Zology. suite101.com/articule. Cfm/ moorhens gallinule-chloropsis.
14. Jassem, E.S.; Hussein, A.J. and Sawad, A.A. (2016). Anatomical, histological and histochemical study of the proventriculus of common moorhen (*Gallinula chloropus*). Bas. J. Vet. Res. 14, 4.
15. Famous, M., Islam, O., Khatun, S., Rahman, M. M., and Ferdoushi, T. (2019). Feeding and management system of turkey in the Sylhet region, Bangladesh. Veterinary Sciences: Research and Reviews, 5(2) :58-65
16. Abood DA, Hussein ZM(2017) : Histological features of Vomer nasal organ in Indigenous Gazelle (*Gazella subgutturosa*). Journal of Entomology and Zoology Studies; 5(4):598-604.
17. Iman M. Khaleel1*, Khalid Ibrahim Al-Khazraji 2 , Muna Hussein AL-Aameli 3(2017):A Comparative Study in some Morphological and Histological Features of the Liver in Gull (*Laruscanus*) and Mallard duck (*Anas platyrhynchos*). Advances in Animal and Veterinary Sciences .5 (7): 307-311.
18. Rodrigues, M.N., J.A.P. Abreu, C. Tivane, P.G. Wanger and D.B. Campos *et al.*, 2012. Microscopical Study of the Digestive Tract of the Blue and Yellow Macaws. In: Current Microscopy Contributions to Advances in Science and Technology, Mendez-Vilas, A. (Ed.). Formatex Research Center, Spain, ISBN-13: 9788493984359, pp: 414-421 [Direct Link](#) |
19. Al-Saffar F.J. and Al-Samawy, E.R.M. (2016). Histomorphological and histochemical study of stomach of domestic pigeon (*Columba livia domestica*).The Iraqi Journal of Veterinary Medicine, 40(1): 89-96.
20. Iman Mousa Khaleel and Abdul Razzaq Baker(2018): Anatomical and Histomorphological Study of the Trachea and Lung in Indigenous Guinea Pigs (*Caviaporcellus*). Inter J Vet Sci, 2018, 7(4): 210-215.
21. Khalaf .AS, Merhish .M (2010): Anatomical Study of the Accessory Genital Glands in Males Sheep (*Ovis aris*) and Goats (*Caprus hircus*) . Iraqi J. Vet. Med. 34 (2): 1 – 8;
22. Aitken, R.N.C., 1958. A histochemical study of the stomach and intestine of the chicken. J. Anatomy, 92: 453-466. [Direct Link](#) |
23. Igwebuik, U.H. and U.U. Eze, 2010. Morphological characteristics of the small intestine of the african pied crow (*Corvus albus*). Anim. Res. Int., 7: 1116-1120. [Direct Link](#) |
24. El-Sayyad, H.I.H., 1995. Structural analysis of the alimentary canal of-hatching Youngs of the owl *Tytoalba*. J. Egypt. Ger. Soc. Zool., 16: 185-202: Dyce, K.M., W.O. Sack and C.J.G. Wensing, 2002. Textbook of Veterinary Anatomy. W.B. Saunders Co., New York, pp: 806-821.
25. Caceci, T., 2003. Avian Digestive System. Academic Press, Ithaca, New York, pp: 94.



26. Zaher, M., A.W. EL-Ghareeb, H. Hamdi and F.A. Amod, 2012. Anatomical, histological and histochemical adaptations of the avian alimentary canal to their food habits: I-*Coturnix coturnix*. Life Sci. J., 9: 253-275.
27. Bezuidenhout, A.J. and G. van Aswegen, 1990. A light microscopic and immunocytochemical study of the gastrointestinal tract of the ostrich (*Struthio camelus* L.). Onderstepoort J. Vet. Res., 57: 37-48. [PubMed](#) | [Direct Link](#) | .
28. Andleeb, R., R.L. Bhardwaj and K.B. Sharma, 2009. Histochemical studies on the small intestine of Gaddi goat. Indian J. Anim. Physiol., 2: 75-78.
29. Aitken, R.N.C., 1958. A histochemical study of the stomach and intestine of the chicken. J. Anatomy, 92: 453-466. [Direct Link](#) | .

